

CASE STUDY

Extending Aortic Aneurysm with Ischemic Small Bowel

INTRODUCTION:

As minimally invasive, easy-to-use devices for monitoring hemodynamically unstable patients are now available, the application of these devices should be considered for more efficient management of their hemodynamics. Arterial pressure-based cardiac output monitoring and central venous oximetry may enable clinicians to manage patients' oxygen delivery more precisely than mean arterial pressure and central venous pressure alone.

CLINICAL EVENTS

Location: UPMC Shadyside, Pittsburgh, PA, USA

Patient Details: 69-year-old male, 6'1", 97.6 kg

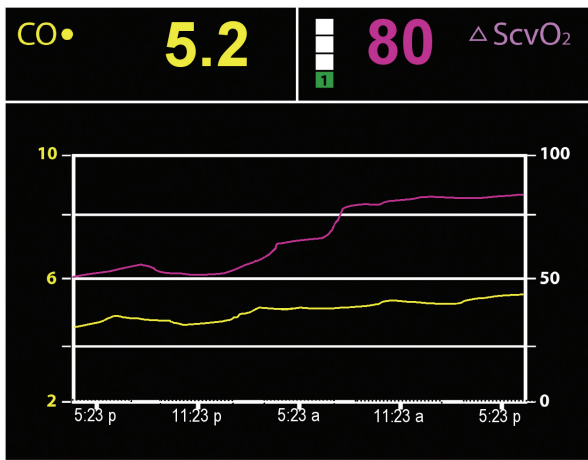
Medical History: Previous medical history revealed questionable hypertension with non-compliant use of medication, alcohol abuse and dependency, and absent regular medical treatment.

CASE NOTES

The patient presented to the Emergency Department in moderate distress and with complaints of severe abdominal discomfort. The patient's abdomen was tender on palpation and distended. A 9-centimeter abdominal aortic aneurysm was revealed on CT scan. Initial blood pressure was over 190 mmHg systolic and 104 mmHg diastolic, and he was transferred to the Medical Intensive Care Unit.

The patient was placed on an esmolol infusion for blood pressure control. On day 2, the patient's mental status deteriorated and his pain increased. The surgical service was consulted and a follow-up CT scan was performed, revealing the high probability of an ischemic small bowel. This diagnosis was based on visualized changes on the CT scan as well as probable partial or complete occlusion of the IMA. Lactate levels were increasing. Based on the findings surgery was initially the treatment of choice but was refused

as an option by the patient. On day 3, lactate level reached 4 mmol/liter and urine output was less than 20cc in 2 hours. Antihypertensive therapy was discontinued, fluids were administered, and low-dose vasopressors for systemic perfusion were added. The patient was transferred to the surgical ICU. A new radial arterial line and arterial pressure-based cardiac output sensor (FloTrac sensor, Edwards Lifesciences, Irvine, CA, USA) was placed, along with a central venous oximetry catheter (PreSep catheter, Edwards Lifesciences, Irvine, CA, USA). Initial readings revealed a cardiac output of 4.6 l/min (cardiac index of 2.4 l/min/m²), heart rate was 113, and ScvO₂ value of 50% with a FiO₂ of 1.0. The patient was sedated, intubated, and mechanically ventilated. The patient's urine output fell to <20 cc/hr with a 24 hour output of 210 cc. His BUN and creatinine rose accordingly to a high of 60 and 2.5. He underwent repeated CT scans.



Over the following 24 hours, the patient’s status was optimized with administration of fluid, packed red blood cells, and low dose vasopressin. Cardiac output increased to 5.2 l/min and ScvO₂ increased to 80%. The figure represents the trends of cardiac output (CO) and central venous saturation (ScvO₂) for the resuscitation period. Within 48 hours, the patient was extubated and the patient was transferred from the ICU on the following day (admission day 8). Upon transfer, laboratory values revealed no renal complications. Liver function was adequate and lactate levels had returned to normal. The patient was

discharged from the hospital on day 12.

Retrospective analysis revealed that the average ICU length of stay for a critically-ill patient with small bowel ischemia at this institution is 15 days and the average hospital length of stay is 25 days. Other key cost parameters are shown in Table 1. Comparing aggregate cost data with the cost for this patient revealed a gross savings of approximately \$56,000.

DISCUSSION

The introduction of less invasive, easy-to-use hemodynamic monitoring devices increases the options available for more effectively managing critically ill patients. This case illustrates the utility of continuously monitoring the fluid status and oxygen consumption of a patient who otherwise would not have been monitored in order to avoid placing a more invasive device. Use of this increased level of monitoring and the resulting treatment regimen demonstrated a significant reduction in healthcare resources in this case study.

Submitted by: Albert Minjock, RN
 Unit Director, SICU
 UPMC Shadyside
 Pittsburgh, PA 15232 USA

Table 1: Comparison of key cost parameters between average patients with this diagnosis and this case

	Average	Case Study
Hospital length of stay	25	12
ICU length of stay	15	8
Ventilator days	6	3
Renal complication rate	24%	none

Rx only. See instructions for use for full prescribing information.

Edwards Lifesciences devices placed on the European market meeting the essential requirements referred to in Article 3 of the Medical Device Directive 93/42/EEC bear the CE marking of conformity.

Edwards is a trademark of Edwards Lifesciences Corporation. Edwards Lifesciences, the stylized E logo, FloTrac and PreSep are trademarks of Edwards Lifesciences Corporation and are registered in the United States Patent and Trademark Office.

© 2007 Edwards Lifesciences LLC
 All rights reserved. AR02684

