

# CONTINUOUS CENTRAL VENOUS SATURATIONS DURING PERICARDIAL TAMPONADE: CASE REPORT

Dr N Spenceley,<sup>1</sup> Dr P Skippen<sup>2</sup>, G Krahn<sup>2</sup>, Dr N Kissoon<sup>2</sup>

<sup>1</sup>: Pediatric Critical Care, Yorkhill Children's Hospital, Glasgow, Scotland <sup>2</sup>: Acute and Critical Care Programs, Department of

f Pediatrics, University of British Columbia, Vancouver, British Columbia, Canada

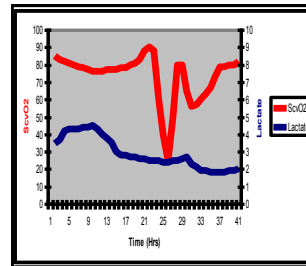
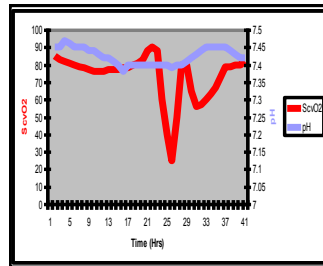
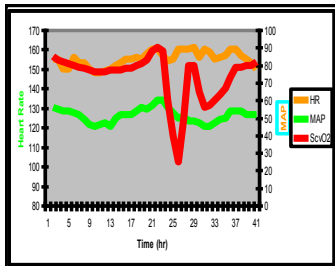
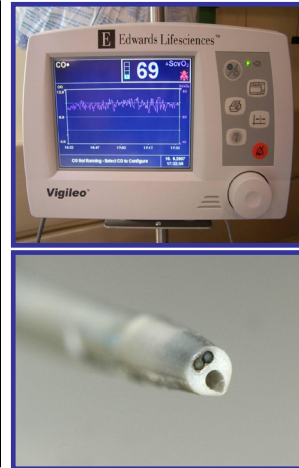## Abstract:

We report the first case of a newly modified central venous catheter (PediaSat™ Oximetry Catheter, Edwards Lifesciences LLC, Irvine, CA, USA) with continuous ScvO<sub>2</sub> monitoring for children. We demonstrate its utility in a patient with impaired oxygen delivery when traditional markers remain stable. This catheter enabled the rapid diagnosis of cardiac compromise due to pericardial effusion, leading to early treatment. Traditional central line functions and insertion technique are maintained.

## Case Report:

A three month old girl, weighing 5.3kgs was admitted to our institution for correction of her congenital heart defect. Prior to surgery a 4.5 Fr Dual lumen Edwards PediaSat™ Oximetry Catheter was inserted percutaneously into the right internal jugular vein using the Seldinger technique. During the operation the catheter was used for routine drug delivery and pressure monitoring. On returning to the PICU a chest radiograph confirmed the tip of the catheter in the superior vena cava. The Vigileo oximetry module was then calibrated using a co-oximetry sample obtained from the distal port of the catheter.

During the second post-operative day a sharp decline in the ScvO<sub>2</sub> from the 70's to the 30's was noted over a period of about 3 hours. Traditional markers of tissue hypoxia, specifically: heart rate, blood pressure, lactate levels and blood gases remained stable. A cardiac echo showed a large pericardial effusion. This was evacuated and the ScvO<sub>2</sub> readings returned to normal over the next few hours.



## Discussion:

Continuous monitoring in the intensive care unit is used to provide early recognition, prevention and treatment of tissue hypoxia in the critically ill. Sometimes, despite normal hemodynamic parameters, significant imbalance between oxygen delivery and consumption exist resulting in occult tissue hypoxia.

Mixed venous saturation (SvO<sub>2</sub>), measured with a pulmonary artery catheter, has been used as an indirect method of assessing tissue oxygenation for many years. Recently, continuous ScvO<sub>2</sub> monitoring has emerged as a surrogate for SvO<sub>2</sub> in adults and now a central venous catheter with this function has been developed for the pediatric population.

Alterations in the ScvO<sub>2</sub> are due to an imbalance between oxygen delivery and consumption. Increased oxygen consumption (VO<sub>2</sub>) or a fall in oxygen delivery (DO<sub>2</sub>) will result in a decreased ScvO<sub>2</sub>. Changes in the ScvO<sub>2</sub> vary minute by minute, therefore in the sedated and ventilated patient with a stable VO<sub>2</sub>, saturation and hemoglobin, a decrease in the ScvO<sub>2</sub> is most likely due to a fall in the cardiac output.

$$\text{Fick Equation: } CO = VO_2 / avO_2.$$

$$\text{Re-arranged for ScvO}_2: ScvO_2 = SaO_2 - VO_2 / CO \times (1.34 \times Hb)$$

Additional potential advantages of this catheter include: rapid evaluation of a specific intervention; less blood draws with the potential reduction in blood transfusions and catheter related blood stream infections; clinician comfort with perhaps less intervention in the face of a normal ScvO<sub>2</sub>

## Summary:

We report this case to illustrate the potential of a new pediatric central venous catheter, with continuous ScvO<sub>2</sub> monitoring for the early detection of evolving tissue hypoxia. The cause in this instance, was impaired cardiac output resulting from a pericardial effusion which could have progressed to tamponade, a condition known to cause morbidity and mortality. A change in ScvO<sub>2</sub> readings from the catheter prompted early diagnosis and treatment. Traditional central line functions and insertion technique are maintained.